

Short Communication

A Rare Case of Polyorchidism in a Cat with Four Intra-abdominal Testes

J Roca-Ferrer, E Rodríguez, GA Ramírez, C Moragas and M Sala

Centre Veterinari Bonavista, Cornellà de Llobregat, Catalonia, Spain

Contents

Polyorchidism is a rare congenital anomaly defined as the presence of more than two histologically proven testes. We report a case of a 9-month-old European cat with four intra-abdominal testes. The diagnosis was performed by means of ultrasonography, intra-operative examination and histological confirmation. The case reported here presents an extremely rare anomaly, as no previous studies in veterinary medicine have reported the presence of four testes. This case suggests that supernumerary testes should be included as differential diagnoses for intra-abdominal masses.

Introduction

Cryptorchidism, the failure of one or both testes to descend into scrotum, is a common congenital abnormality. This anomaly was described by de Graaf in 1668 in respect to humans, dogs and rams (Amann and Veeramachaneni 2007). The incidence of feline cryptorchidism in two studies on cats presented for neutering was 1.3% in 3806 animals over a period of 4.5 years (Yates et al. 2003) and 1.8% in 1345 cats during a 10-year period (Millis et al. 1992). The prevalence in Persian cats seemed to be higher than in other breeds (Millis et al. 1992). The existence of predisposition for location of undescended testes is a matter of debate. Yates et al. reported that left- or right-sided inguinal cryptorchidism was the most common forms in the studied cats (Yates et al. 2003). However, Millis et al. reported that there was no predisposition for location of undescended testes (abdominal versus inguinal or right versus left side) in unilateral cryptorchid cats. However, in the same study, all cats with bilateral cryptorchidism had abnormally located testes (Millis et al. 1992). More recently, Steckel, in a study where 4 feline cases were described, reported that all the undescended testes were located in the inguinal region (Steckel 2011).

Polyorchidism, the presence of more than two testes, is an uncommon congenital anomaly both in human and veterinary medicine. The first reports of polyorchidism in veterinary medicine were concerned with the finding of supernumerary testes in horses as incidental events during castration (Earnshaw 1959) while in humans the first case was reported during a routine autopsy in 1670 (Bergholz and Wenke 2009). The number of cases reported in the literature is very low. In veterinary medicine, five cases have been published up to now, as illustrated in Table 1. In human medicine, 140 cases have been reported (Bergholz and Wenke 2009). In both veterinary and human medicine, the most common case of polyorchidism is the presence of a single supernumerary testis (triorchidism). All the veterinary publications reported triorchidism (Table 1). In humans, among the 140 patients, only six cases with four testes were found (Bergholz and Wenke 2009). In both veterinary and human patients, supernumerary testes were mainly located in the scrotal region, although they are also frequently associated with cryptorchidism.

Even if supernumerary testes can be suspected on clinical examination or during image analysis, the diagnosis of polyorchidism should include histological confirmation. An encysted firm hydrocele, spermatocele or testicular neoplasm, among others, could be mistaken for a supernumerary testis during clinical examination (Bergholz and Wenke 2009). Moreover, high-resolution image techniques do not allow to make a reliable diagnosis, as it is not possible to differentiate supernumerary testes from other intra-escrotal or intra-abdominal masses (Bergholz and Wenke 2009).

Here, we report a case of a cat with four intra-abdominal testes. The diagnosis was performed by means of ultrasonography, intra-operative examination

Table 1. Previous reported polyorchidism in veterinary medicine

Especie	Surgical procedure	Number of testes	Ultrasonographic image	Histologic analysis	Testes location	Year	Reference
Horse	Routine Castration	3	No	No	1 in left scrotum 2 in right scrotum	1959	Earnshaw (1959)
Cat	Routine castration	3	No	Yes	1 in left scrotum 2 in right scrotum	1999	Milwright and Smith (1999)
Dog	Therapeutic castration	3	No	No	1 in right scrotum 2 abdominal testis	1999	Atkinson (1999)
Horse	Routine castration	3	No	No	1 in left scrotum 2 in right scrotum	2010	Davies (2010)
Dog	Therapeutic castration	3	Yes	Yes	1 in right scrotum 2 abdominal testis	2012	Tamminen et al. (2012)

and histological analysis. This rare anomaly has not been previously reported in the veterinary literature.

The Clinical Case

A 9-month-old male European cat was presented for routine castration. The cat started the sexual behaviour 1 month before the visit. On physical examination, there were testes neither in the scrotal sacs nor in the inguinal area. To confirm the cryptorchidism, an abdominal ultrasound examination was performed (Zonare ultrasound scanner with 12 MHz probe, Zonare Medical Systems, Mountain View, CA, USA).

On sonography, one round-shaped (5 mm diameter), hypoechoic and homogeneous structure was found at the mid-point between the caudal pole of the left kidney and the inguinal area (Fig. 1a). A centrally located hyperechoic focus compatible with the mediastinum of the testis was detected. Examination of the right abdominal area evidenced three structures with similar size, position and echogenicity (Fig. 1b and c). There were no focal lesions suspicious of malignancy in any of the four structures. Additionally, it was not possible to detect blood flow in any of the four structures using the Doppler mode exploration. As these findings were compatible with a diagnosis of supernumerary atrophic testes, exploratory laparotomy was performed.

Surgical technique was made through a ventral midline. Intra-operatively, one 5-mm testis with normal macroscopic morphology was found on the left side (Fig. 2a). On the right side, three 5-mm testes with normal macroscopic morphology were found (Fig. 2b). All testes showed their own epididymis, but the three testes shared a common ductus deferens. Orchiectomy was performed and the testes were histologically examined to confirm the diagnosis.

Testes were fixed in 10% neutral buffered formalin, trimmed, dehydrated through graded alcohols, embedded in paraffin wax, sectioned at 3 μ m and stained with haematoxylin and eosin (HE) for routine histopathological examination. Microscopically, all the specimens were comparable. The seminiferous tubular compartment appeared smaller than normal (Fig. 3a) and was composed of large, elongated to globoid, frequently vacuolated Sertoli cells (Fig. 3b). Lumen of some tubules was obliterated by apical, elongated cytoplasmic projections of these cells. Rare germinal cells were found in some tubules after serial sections were performed. They were large, round to polygonal cells containing abundant acidophilic cytoplasm and ovoid single or multiple nuclei with basophilic, large, centrally placed nucleoli (Fig. 3c). Mature spermatozoa were not seen. Leydig cell from the interstitial or intertubular compartment was slightly increased in number in two of the supernumerary testes. These cells were large, irregularly spherical to polyhedral and showed relatively small, usually spherical and eccentrically placed nuclei with small single nucleoli (Fig. 3b). Atypia was not observed. Epididymides were composed of small tubules lined by single columnar epithelia and surrounded of loose, fibrocollagenous interstitial tissue (Fig. 3a). Lumens did not contain mature spermatozoa. A focus of disorganized testicular parenchyma was

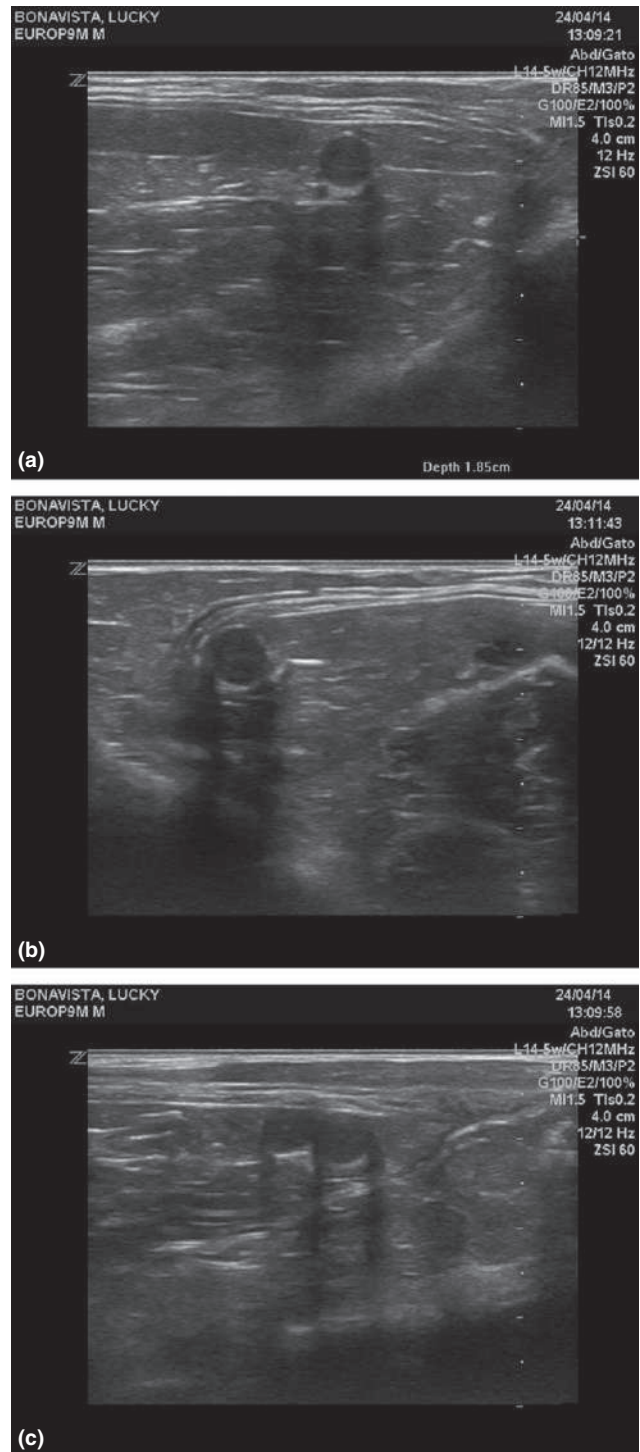


Fig. 1. Abdominal ultrasonographic exploration. Images of the left cryptorchid testis (a) and the three right cryptorchid testes (b and c) obtained in longitudinal sections

noted within the visceral lamina of tunica vaginalis in one of the supernumerary testes. It was composed of small atrophic seminiferous tubules with vacuolated Sertoli cells surrounded by small nests of Leydig cells (Fig. 4).

The postoperative period was uneventful. There was definitive absence of sexual behaviour in a visit 4 weeks after the surgery.

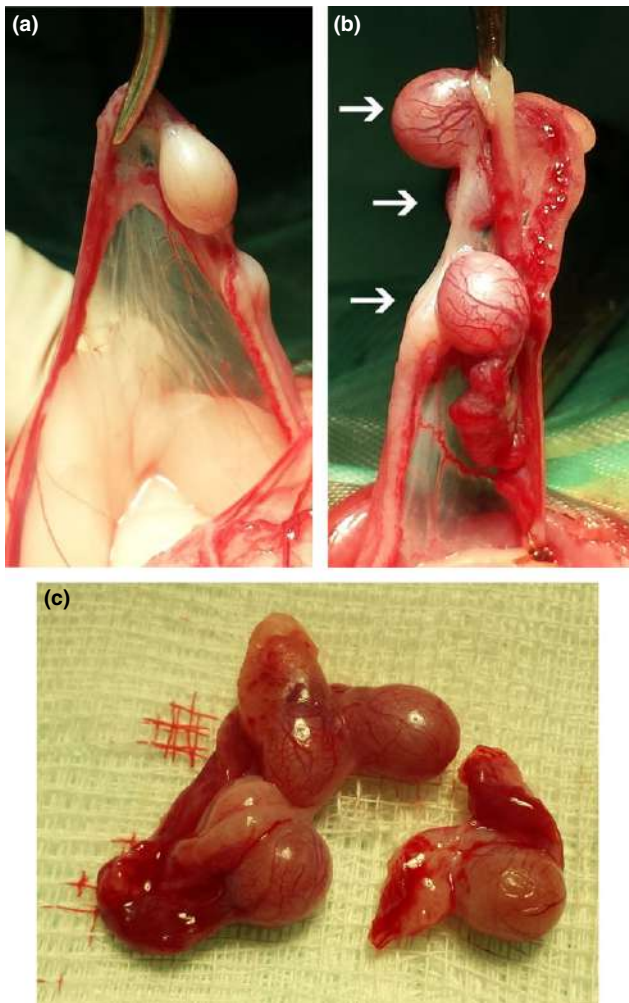


Fig. 2. Intra-operative photographs. (a) Left cryptorchid testis and (b) three right cryptorchid testes (white arrows). Panel (c) shows the four testes

Discussion

We report a case of cryptorchidism with four intra-abdominal testes in a 9-month-old European cat. The

patient was affected by two congenital anomalies: cryptorchidism and polyorchidism.

Cryptorchidism is a common congenital disease in which genetic, epigenetic and environmental factors seem to play a role. After differentiation, testes reached the scrotum in three phases: abdominal translocation, transinguinal migration and inguinoscrotal migration (Amann and Veeramachaneni 2007). Several genes are responsible for the testicular descent, such as androgen receptor, calcitonin gene-related peptide, insulin-like peptide 3 and testosterone, among others (Amann and Veeramachaneni 2007; Meyers-Wallen 2009). It has been suggested that the position of a cryptorchid testis depends on the altered phase of testicular descent. In the case reported in this study, the cat suffered from bilateral abdominal cryptorchidism, with no presence of any testis in scrotal sacs. This localization of the testes strongly suggests that abdominal testis translocation began but could not be accomplished, being insulin-like peptide 3 and testosterone the main signal regulating this process (Amann and Veeramachaneni 2007; Meyers-Wallen 2009).

Feline polyorchidism is a very rare finding. The prevalence remains unknown because there are not large screening studies published to date. Moreover, even if the presence of supernumerary testis can be suspected by intra-operative examination or imaging techniques, the diagnosis of polyorchidism should be confirmed by histological analysis. To our knowledge, it has been reported only one case of cat with polyorchidism (Milwright and Smith 1999). In that case, three testes were found during routine castration: one testis was located in the left scrotum and two testes were found in the right scrotum. The case reported here presents an extremely rare anomaly, as no previous studies in veterinary medicine have reported the presence of four testes. Moreover, the previous reported cases of polyorchidism with cryptorchidism showed, at least, one testis in scrotum (Table 1).

Histologically, presence of Sertoli cells in seminiferous tubules ('Sertoli cell-only' pattern) is characteristic of cryptorchid testes because of the deleterious effect of body temperature on spermatogenesis and germinal

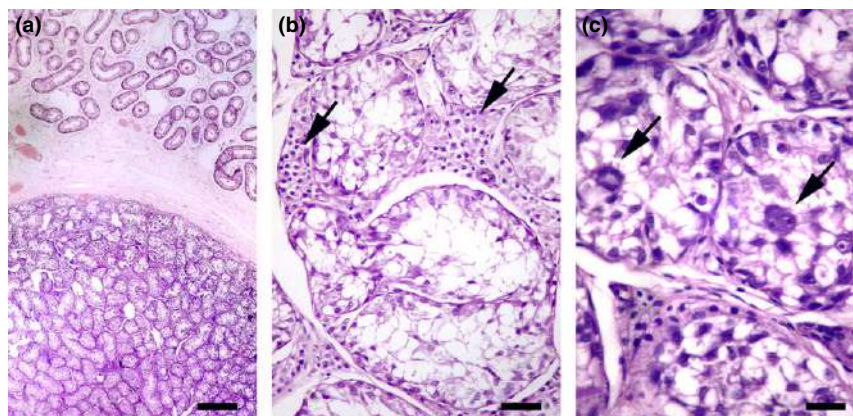


Fig. 3. Histologic examination. (a) Low magnification showing small appearance of both epididymis and testicular parenchyma. Bar = 250 μ m. HE stain. (b) Seminiferous tubules were usually filled by large, vacuolated Sertoli cells. Germinal cells were not commonly observed. Interstitial Leydig cells were hyperplastic in appearance in some areas (arrows). Bar = 50 μ m. HE stain. (c) When serial sections were performed, intra-tubular atypical germinal cells and multinucleated spermatogonia (arrows) were rarely seen. Bar = 25 μ m. HE stain

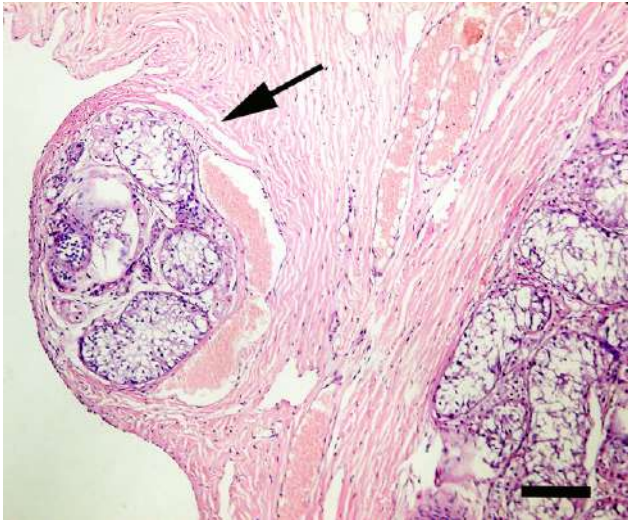


Fig. 4. Histologic examination. Microphotograph shows disorganized atrophic testicular parenchyma within the visceral lamina of tunica vaginalis. Bar = 100 μ m. HE stain

cells (Foster and Ladds 2007). Histological features consistent with neoplastic transformation on this cell component were not noted in our case. Such tubules should be examined carefully for the occurrence of so-called atypical germinal cells suggested to be 'in situ' neoplasms (Hedinger 1982). When serial sections were performed, atypical germinal-like cells, including some multinucleated spermatogonia, were rarely noted in some tubules in the case presented herein. Multinucleated spermatogonia are an abnormality present in cryptorchidism, in addition to other testicular degeneration processes, and may be associated with an increased risk of testicular malignancy later in life (Cortes et al. 2003). An apparent hyperplasia of Leydig cells was also observed in two of the supernumerary testes. Leydig cells hyperplasia is usually presented as nodular or diffuse proliferation. These cells may produce testosterone and estradiol resulting in clinical signs such as hypersexual behaviour or gynaecomastia (Foster and Ladds 2007). Therefore, the abnormal behaviour presented by our patient could be consequence of this feature. The apparent diffuse hyperplasia of interstitial endocrine cells in cryptorchid and hypoplastic testes does not predispose to the development of tumours (Foster and Ladds 2007). A small focus of ectopic testicular tissue was also noted within the vaginal tunica in one of the supernumerary testes. During embryological development, extragonadal migration of the Sertoli and interstitial cell primordia may seed microscopic foci of these cells in a paratesticular location (Amodio et al. 2004). Considering the context of polyorchidism in this case, abnormal migration during the duplication or division of the genital ridge could account for this rare finding.

References

Amann RP, Veeramachaneni DNR, 2007: Cryptorchidism in common eutherian mammals. *Reproduction* **133**, 541–561.

Amodio JB, Maybody M, Slowotsky C, Fried K, Foresto C, 2004: Polyorchidism: Report of three cases and review of the literature. *J Ultrasound Med* **23**, 951–957.

Atkinson MC, 1999: Polyorchidism in a dog. *Vet Rec* **145**, 711–712.

Bergholz R, Wenke K, 2009: Polyorchidism: a meta-analysis. *J Urol* **182**, 2422–2427.

The exact mechanism for occurrence of polyorchidism is still not known. Several hypotheses have been proposed to explain the development of extra testes during the embryogenesis. In fact, depending on the events that lead to the different types of polyorchidism, many classifications have been proposed. The most accepted is the Leung classification (Leung 1988), which describes four forms of polyorchidism depending on the anatomy of the testes. In type I, the supernumerary testis lacks an epididymis or vas deferens and has no attachment to the usual testis. In type II, the supernumerary testis drains into epididymis of usual testis, and they share a common vas deferens. In type III, the supernumerary testis has its own epididymis and epididymis of both ipsilateral testes drains into a common vas deferens. Finally, in type IV, there is a complete duplication of testis, epididymis and vas deferens. According to this classification, the present case was consistent with type III, as the three testes drain in one vas deferens.

In veterinary medicine, five cases of polyorchidism have been reported. These cases are summarized in Table 1. In all cases, three testes have been found. In three cases, all testes were in the scrotum (Earnshaw 1959; Milwright and Smith 1999; Davies 2010), while in two cases, two testes were found in abdomen and 1 testis was located in scrotum (Atkinson 1999; Tamminen et al. 2012). Moreover, among these five cases, histological analyses were performed only in two (Milwright and Smith 1999; Tamminen et al. 2012) and ultrasonographical diagnosis just in one (Tamminen et al. 2012).

Additionally, this case suggests that supernumerary testes should be included as differential diagnoses for intra-abdominal masses, even in cats supposed to be neutered.

In conclusion, we report for first time the case of polyorchidism with cryptorchidism in a cat with four intra-abdominal testes.

Acknowledgements

The work has been supported by the Centre Veterinari Bonavista.

Conflict of interest

None of the authors have any conflict of interest to declare.

Author contributions

J Roca-Ferrer designed examinations and treatment, performed the surgical procedure and wrote the manuscript. E Rodríguez performed the surgical procedure, read and corrected the manuscript. GA Ramírez analysed histological samples and wrote the manuscript. C Moragas performed ultrasonographic examinations, read and corrected the manuscript. M Sala performed the surgical procedure, read and corrected the manuscript.

- Cortes D, Thorup J, Visfeldt J, 2003: Multinucleated spermatogonia in cryptorchid boys: a possible association with an increased risk of testicular malignancy later in life? *APMIS* **111**, 25–30.
- Davies EV, 2010: Polyorchidism in a horse. *Vet Rec* **167**, 310.
- Earnshaw RE, 1959: Polyorchidism. *Can J Comp Med Vet Sci* **23**, 66.
- Foster RA, Ladds PW, 2007: Male genital system. In: Maxie MG (ed.), *Jubb, Kennedy, and Palmer's Pathology of Domestic Animals*. WB Saunders Company, Edinburg, Scotland, UK, pp. 573–580.
- Hedinger CE, 1982: Histopathology of undescended testes. *Eur J Pediatr* **139**, 266–271.
- Leung AK, 1988: Polyorchidism. *Am Fam Physician* **38**, 153–156.
- Meyers-Wallen VN, 2009: Review and update: genomic and molecular advances in sex determination and differentiation in small animals. *Reprod Domest Anim* **44**, 40–46.
- Millis DL, Hauptman JG, Johnson CA, 1992: Cryptorchidism and monorchism in cats: 25 cases (1980–1989). *J Am Vet Med Assoc* **200**, 1128–1130.
- Milwright RDP, Smith KC, 1999: Polyorchidism in a cat. *Vet Rec* **4**, 679–680.
- Steckel RR, 2011: Use of an inguinal approach adapted from equine surgery for cryptorchidectomy in dogs and cats: 26 cases (1999–2010). *J Am Vet Med Assoc* **239**, 1098–1103.
- Tamminen TM, Leinonen MR, Käck H, Andersson M, 2012: A polyorchid dog. *Reprod Domest Anim* **47**, e26–e28.
- Yates D, Hayes G, Heffernan M, Beynon R, 2003: Incidence of cryptorchidism in dogs and cats. *Vet Rec* **152**, 502–504.

Submitted: 1 Jul 2014; Accepted: 3 Nov 2014

Author's address (for correspondence): Jordi Roca Ferrer, Centre Veterinari Bonavista, c/ Bonavista 15, 08940 – Cornellà de Llobregat, Catalonia, Spain.
E-mail: rocaferrer@gmail.com